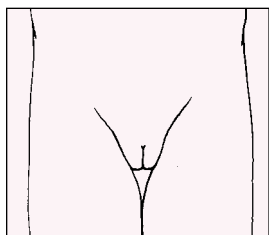


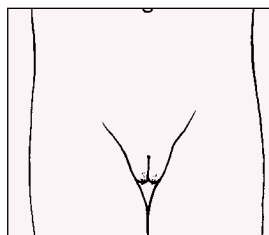


# Tanner Staging

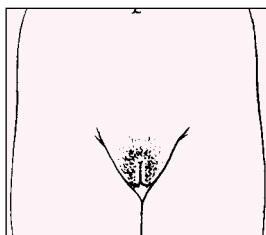
## Staging Pubic Hair Development



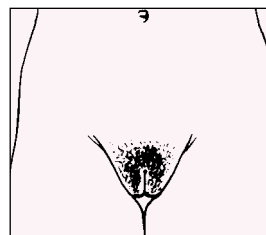
**Pubic Hair Stage 1**  
Prepubertal. The vellus over the pubis is no further developed than that over the abdominal wall, ie, no pubic hair.



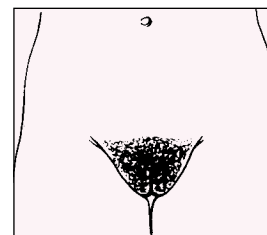
**Pubic Hair Stage 2**  
Sparse growth of slightly pigmented, longer but still downy hair, straight or only slightly curled, appearing chiefly along the labia.



**Pubic Hair Stage 3**  
The hair is considerably darker, coarser, and more curled. The hair spreads sparsely over the mons.

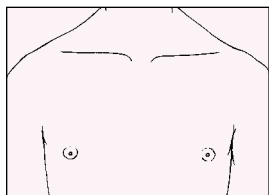


**Pubic Hair Stage 4**  
The hair now resembles adult type. The area covered is still smaller than that in the adult, but the hair is beginning to spread across the mons. There is no hair spread to the medial thighs.

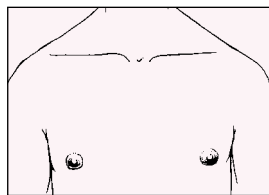


**Pubic Hair Stage 5**  
The hair is adult in type and quantity; darker, coarse, and curled; and distributed in the classic female triangle. Some individuals may have hair spread to the medial thighs.

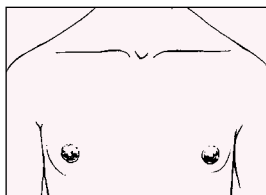
## Staging Breast Development



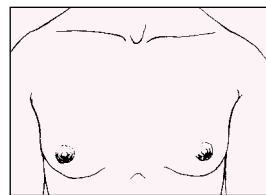
**Breast Stage 1**  
There is no development. Only the papilla is elevated.



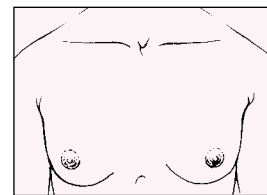
**Breast Stage 2**  
The "breast bud" stage. The areola widens, darkens slightly, and elevates from the rest of the breast as a small mound. A bud of breast tissue is palpable below the nipple.



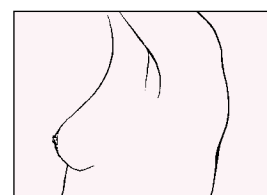
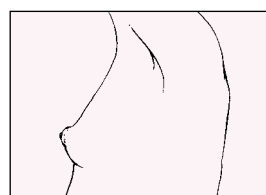
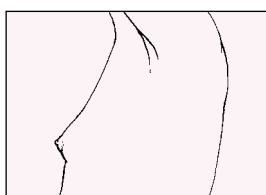
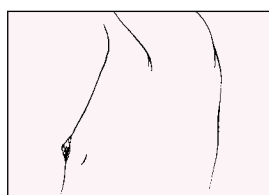
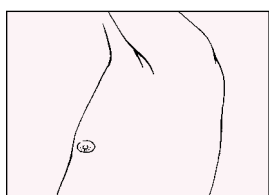
**Breast Stage 3**  
The breast and areola further enlarge and present a rounded contour. There is no separation of contour between the nipple and areola and the rest of the breast. The breast tissue creates a small cone.



**Breast Stage 4**  
The breast continues to expand. The papilla and areola project to form a secondary mound above the rest of the breast tissue.



**Breast Stage 5**  
The mature adult stage. The secondary mound made by the areola and nipple, present in Stage 4, disappears. Only the papilla projects. The diameter of the breast tissue (as opposed to the height) has extended to cover most of the area between the sternum and lateral chest wall.



Determining the degree of development of pubic hair and the breasts in adolescents is an essential part of the physical examination. Accurate staging provides an important basis for the management of certain clinical problems that may arise throughout puberty. In addition, counseling regarding the expected timing and sequence of pubertal development depends on recording and understanding the stages of development. The above diagrams detail the various stages of secondary sexual development using the system described by Tanner.

Reprinted with permission. Herman-Giddens, ME, Bourdony CJ. Assessment of sexual maturity stages in girls. Report MA0089. Elk Grove Village (IL): American Academy of Pediatrics; 1995. Copyright © 1995 American Academy of Pediatrics.

